

GUIDED BONE REGENERATION
USING A BOVINE COLLAGEN
MEMBRANE, PLATELET-RICH PLASMA
AND ALLOGENEIC BONE PUTTY

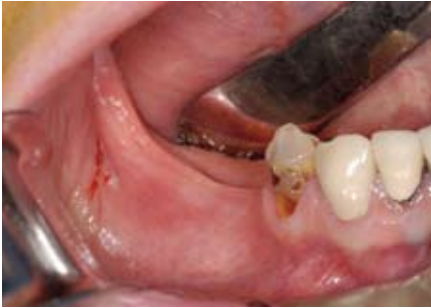

Fig 1

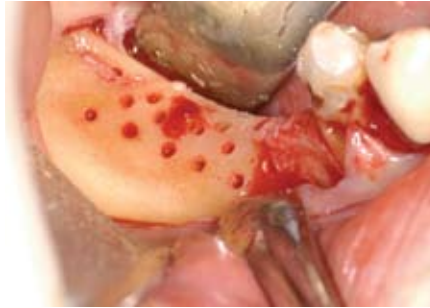

Fig 2

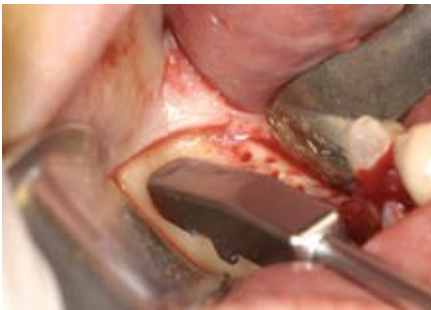

Fig 3a

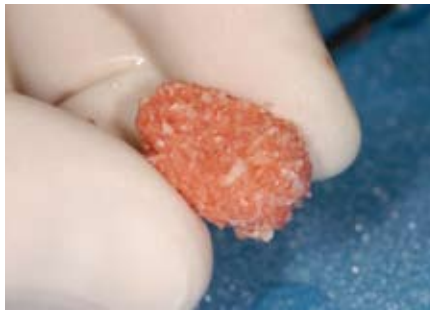

Fig 3b

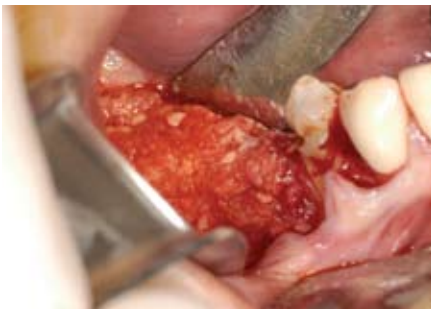

Fig 4a



Fig 4b

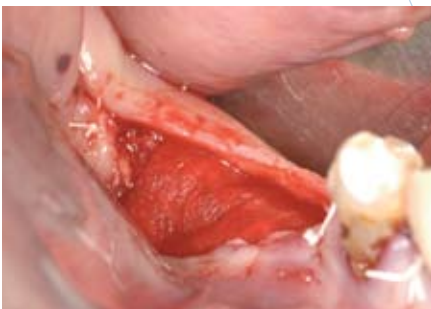

Fig 5a

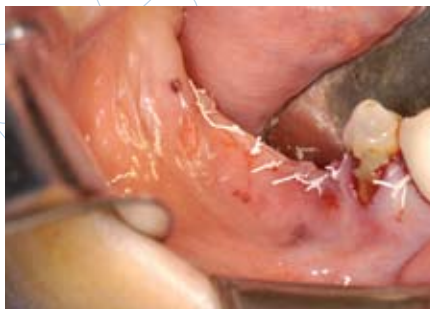

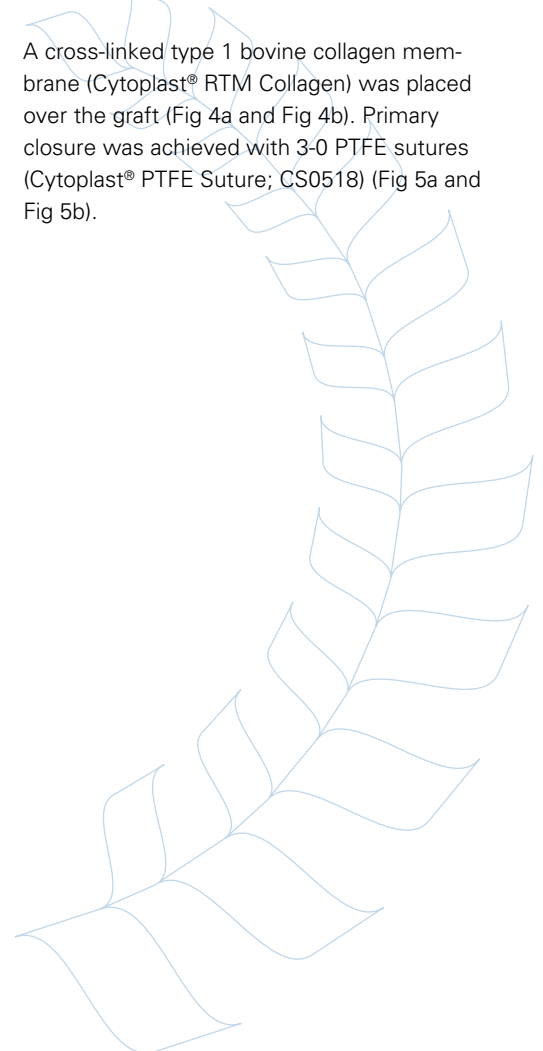
Fig 5b

A 43 year-old female presented for replacement of the mandibular right first molar and second premolar. The teeth had been extracted 20 years previously. There was a combined hard and soft tissue defect requiring augmentation prior to implant placement (Fig 1).

A mid-crestal incision was used to expose the atrophic edentulous ridge. A surgical burr was used to decorticate the bone in preparation for grafting (Fig 2).

Allogeneic bone putty (Regenaform® Moldable Allograft Paste, Exactech Dental Biologics) was hydrated with PRP and then mixed with autogenous cortical bone harvested with a bone scraper (Fig 3a and Fig 3b).

A cross-linked type 1 bovine collagen membrane (Cytoplast® RTM Collagen) was placed over the graft (Fig 4a and Fig 4b). Primary closure was achieved with 3-0 PTFE sutures (Cytoplast® PTFE Suture; CS0518) (Fig 5a and Fig 5b).



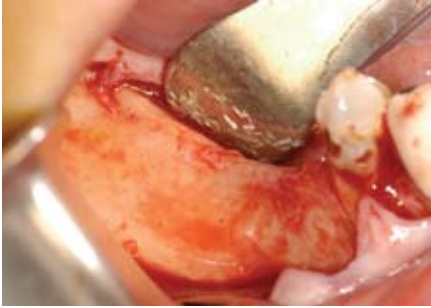


Fig 6

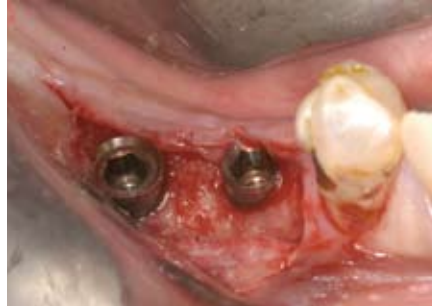

Fig 7

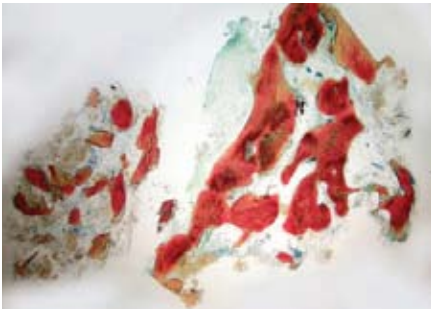


Fig 8

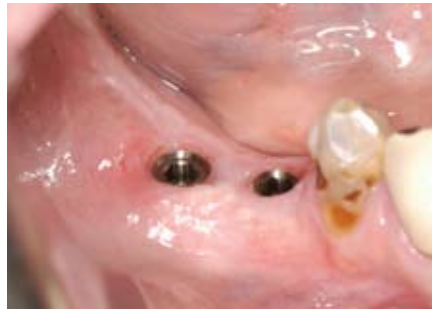

Fig 9

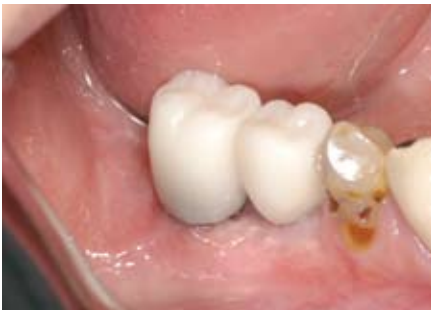

Fig 10

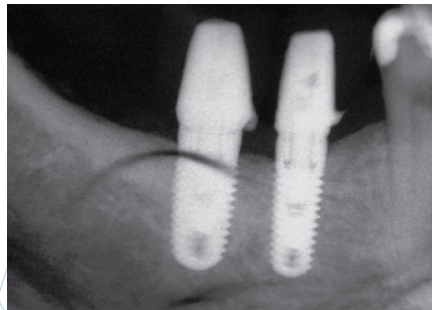


Fig 11

Six months after ridge augmentation (Fig 6), endosseous implants were placed. The augmented bone was of adequate volume and density for uncomplicated implant placement (Fig 7).

A bone core, harvested with a trephine drill from the implant site and examined microscopically (Fig 8), revealed 43% bone by volume with 97% vital bone and 3% residual graft material (Histology by Michael D. Rohrer, DDS, MS. University of Minnesota Hard Tissue Research Laboratory).

Clinically, an increase in the width of keratinized gingiva was seen (Fig 9). Four months after implant placement, the restorative components were placed and the implants were restored with acrylic restorations and progressively loaded (Fig 10 and Fig 11).

SUMMARY

This case demonstrates the successful augmentation of an atrophic, edentulous posterior mandible using guided bone regeneration. The use of a cross-linked type 1 bovine collagen membrane in conjunction with mineralized and demineralized allograft putty resulted in regeneration of vital bone of sufficient volume and density to accommodate a wide diameter implant. This was accomplished in a single surgical procedure using an autogenous graft component harvested locally without the use of a second surgical site. Histological analysis revealed vital bone with remodeling of the allograft particles and continued bone formation at six months.

Cytoplast® is a registered trademark of Osteogenics Biomedical, Inc.

Regenaform® is processed by Regeneration Technologies and distributed by Exactech Dental Biologics.

© 2008 Osteogenics Biomedical, Inc.
BBDI0607