

Multi-site Ridge Preservation/ Reconstruction Porcine Xenograft and dPTFE Membrane

Dan Cullum, DDS

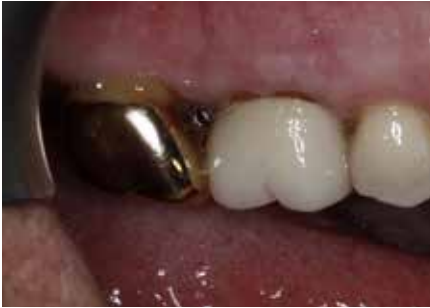

Fig 1

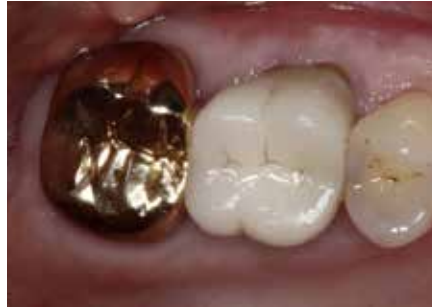

Fig 2

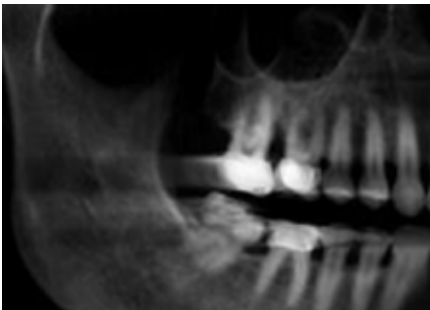


Fig 3

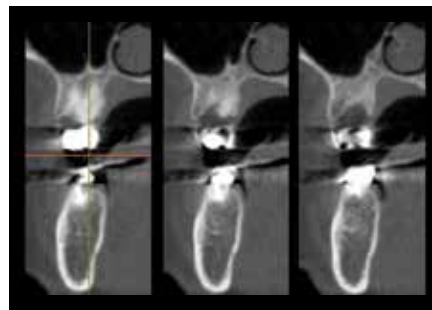


Fig 4

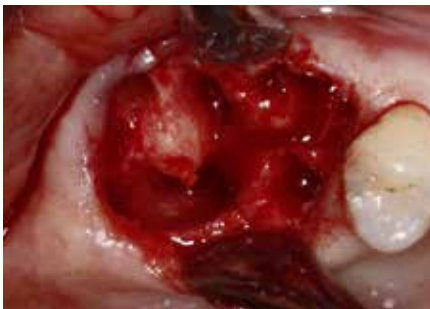

Fig 5

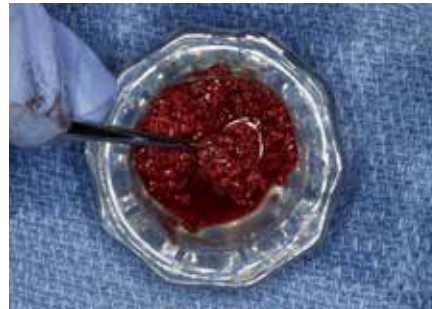


Fig 6

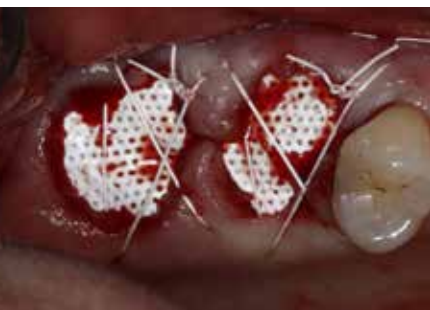

Fig 7

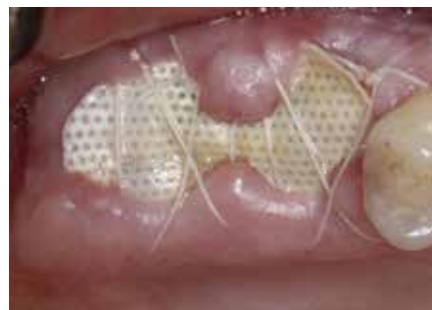

Fig 8

A 68 year-old female patient presented with refractory periodontal disease in the maxillary right first and second molar teeth. The patient requested removal of the failing teeth and implant reconstruction as she was concerned with loss of function. The clinical exam revealed recession, bleeding on probing and 10 mm pocket depths (Fig 1-2). Radiographic evaluation revealed vertical bony defects with furcation involvement (Fig 3-4). Her oral hygiene at the time of the exam appeared adequate. The medical history was non-contributory. A delayed approach was selected due to concern for achieving control of the periodontal disease, with preservation and reconstruction of the horizontal, vertical and intra-bony defects. Re-evaluation was planned after healing to confirm adequate periodontal disease control prior to reconstruction with implant supported restorations.

The teeth were extracted using minimally invasive protocols to preserve the residual bony housing and soft tissue architecture. Significant interproximal and inter-furcal vertical bony defects were observed (Fig 5) and the sockets were carefully debrided. Minimal peripheral periosteal elevation was done for placement of dPTFE (dense polytetrafluoroethylene) membranes (Cytoplast™ TXT 200) after grafting. The extraction defects were then grafted with porcine-derived cancellous xenograft particles (Zcore™) saturated with autologous venous blood (Fig 6).

The dPTFE membranes were trimmed and placed in the sub-periosteal space between the periosteum and the existing bony housing. Next, the soft tissues and membrane are stabilized using 4-0 PTFE (Cytoplast™) with a combination of mattress and interrupted sutures (Fig 7). The impervious nature of the dPTFE membranes allows direct exposure to the oral cavity without risk of bacterial penetration into the surgical site. Advantages of the open grafting technique include preservation of the muco-gingival junction and maintenance of vestibular depth, as the exposed dPTFE membrane minimalizes the need for flap elevation and avoids the need for flap advancement for primary closure.

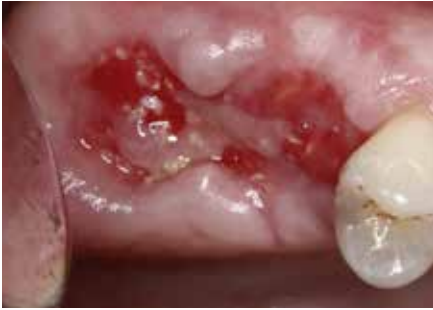

Fig 9

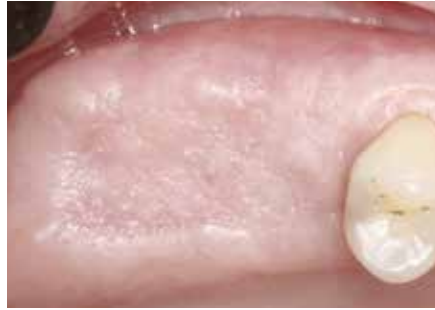

Fig 10

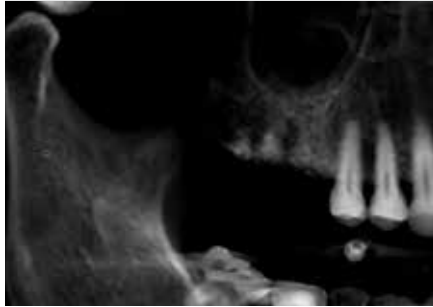


Fig 11

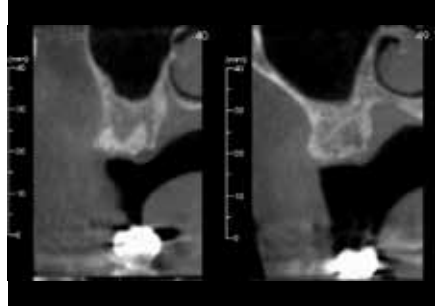


Fig 12a & 12b

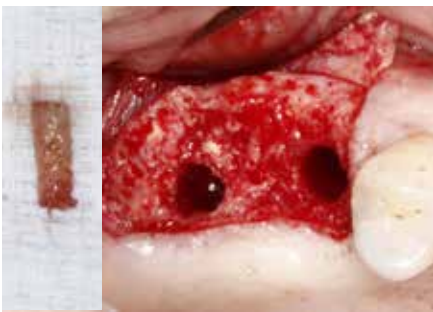


Fig 13a & 13b

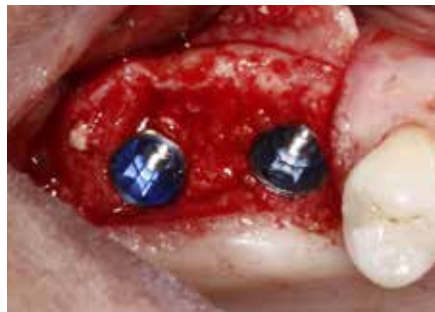

Fig 14

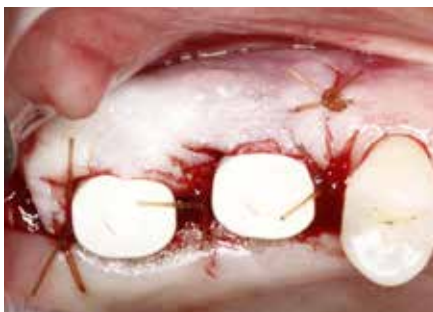

Fig 15




Fig 16

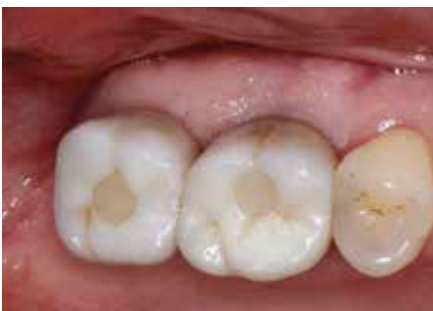

Fig 17

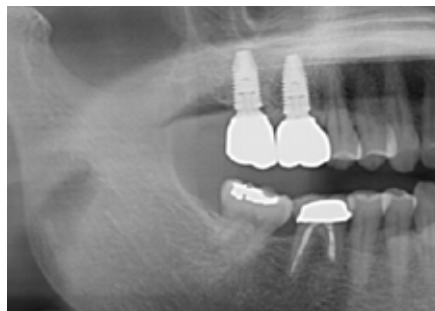


Fig 18

At two weeks post-op, undisturbed healing of the sites was noted. Slight discoloration and plaque accumulation on the dPTFE membranes was noted, with no signs of inflammation or swelling of the surgical site (Fig 8). At that time the sutures were removed.

At five weeks the patient returned and the membrane was removed. The surgical sites demonstrated excellent healing, uncontaminated by bacteria (Fig 9).

After six months the soft tissues have completely healed and a wide band of attached gingival tissue can be observed (Fig 10). The soft tissue architecture and vestibular depth has been maintained as a direct result of avoiding flap elevation and advancement for primary closure at the initial surgery. Radiographic images demonstrate excellent bony healing and ridge dimensions (Fig 11 - 12a & b).

The implant surgical site was exposed with a palatally incised, buccal-based flap for planned apical flap positioning on closure. The grafted sites were fully incorporated and excellent bone volume preservation for implant placement was seen. X-Nav® dynamic navigational surgery was used to harvest a bone core with a 3mm trephine at the grafted first molar site for histological evaluation (Fig 13a & 16). Implant site preparation was completed using dynamic navigation and a combined osteotome sinus floor elevation at the second molar site (Fig 13b).

5.5 mm wide platform conical connection implants were then placed at the molar sites (Fig 14). Expanded emergence PEEK healing abutments were used to develop proper emergence profile. Chromic gut (4-0) suture was used with an interrupted suturing technique to approximate the wound margins and stabilize the apically-positioned flap (Fig 15). Immediate post-op radiograph confirms implant placement.

At four months post-implant placement the patient was released for restoration. Definitive restorations were placed with an optimal functional and esthetic result (Fig 17) and the post treatment radiograph can be seen in Figure 18.