

Vertical Ridge Augmentation with Titanium-Reinforced, Dense-PTFE Membranes and a Combination of Particulated Autogenous Bone and Anorganic Bovine Bone-Derived Mineral: A Prospective Case Series in 19 Patients

Istvan A. Urban, DMD, MD¹/Jaime L. Lozada, DMD²/Sascha A. Jovanovic, DDS, MS³/
Heiner Nagursky, PhD⁴/Katalin Nagy, DDS, PhD⁵

Purpose: This prospective case series evaluated the use of a new titanium-reinforced nonresorbable membrane (high-density polytetrafluoroethylene), in combination with a mixture of anorganic bovine bone-derived mineral (ABBM) and autogenous particulated bone, for vertical augmentation of deficient alveolar ridges.

Materials and Methods: A mixture of ABBM and autogenous particulated bone was used for vertical ridge augmentation and covered with a new titanium-reinforced nonresorbable membrane. Ridge measurements were obtained before and after the procedure, complications were recorded, and biopsy specimens were taken for histologic examination. **Results:** Twenty vertical ridge augmentation procedures were carried out in 19 patients. All treated defect sites exhibited excellent bone formation, with an average bone gain of 5.45 mm (standard deviation 1.93 mm). The healing period was uneventful, and no complications were observed. Eight specimens were examined histologically; on average, autogenous or regenerated bone represented 36.6% of the specimens, ABBM 16.6%, and marrow space 46.8%. No inflammatory responses or foreign-body reactions were noted in the specimens. **Conclusion:** The treatment of vertically deficient alveolar ridges with guided bone regeneration using a mixture of autogenous bone and ABBM and a new titanium-reinforced nonresorbable membrane can be considered successful. *INT J ORAL MAXILLOFAC IMPLANTS* 2014;29:185–193. doi: 10.11607/jomi.3346

Key words: anorganic bovine bone-derived mineral, case series, guided bone regeneration, nonresorbable membrane, vertical augmentation

Augmentation utilizing guided bone regeneration (GBR) has become a major treatment option to provide optimal bone support for osseointegrated dental implants. GBR was initially employed to treat simple defects, including dehiscence and fenestration defects.^{1–3} In addition, GBR has been utilized for

horizontal and vertical ridge augmentations^{4–16} and has demonstrated reproducible outcomes, with high implant survival rates and low complication rates.^{17–20}

The results of recent clinical and histologic studies of ridge augmentation with GBR indicated that anorganic bovine bone-derived mineral (ABBM) mixed with autogenous particulated bone may be a suitable material for staged localized ridge augmentation in both horizontal and vertical augmentations.^{6,7,14} Many studies previously reported on vertical augmentation using a nonresorbable titanium-reinforced expanded polytetrafluoroethylene membrane,^{8–16} but this membrane is no longer commercially available.

Recently, a new high-density polytetrafluoroethylene membrane with titanium reinforcement has become commercially available. However, there are no published reports of its prospective use in the treatment of vertical ridge defects. The purpose of the prospective clinical case series presented herein was to evaluate, clinically and histologically, the use of this new membrane, in combination with a mixture of ABBM and autogenous particulated bone, for vertical augmentation of deficient alveolar ridges.

¹Assistant Professor, Graduate Implant Dentistry, Loma Linda University, Loma Linda, California, USA; Private Practice in Periodontics and Implant Dentistry, Budapest, Hungary.

²Professor, Department of Restorative Dentistry, Director of Graduate Implant Dentistry, Loma Linda University, Loma Linda, California, USA.

³Private Practice in Periodontics and Implant Dentistry, Academic Chairman, gIDE Institute, Los Angeles, California, USA.

⁴Head, CTA Cell Tissue Analysis, Department of Oral and Maxillofacial Surgery, University Clinic of Freiburg, Freiburg, Germany.

⁵Professor and Head of Oral Surgery, Dean, Faculty of Dentistry, University of Szeged, Szeged, Hungary.

Correspondence to: Istvan Urban, Sodras utca 9, Budapest, 1026 Hungary. Fax: +36-1-2004447. Email: Istvan@implant.hu

©2014 by Quintessence Publishing Co Inc.

MATERIALS AND METHODS

This case series reports on patients who presented to a clinical practice and were consecutively treated with vertical ridge augmentation using GBR and particulated composite bone grafts between January 2010 and May 2012. All patients required augmentation of a vertically deficient ridge for subsequent implant placement; some patients also required sinus floor elevation. All patients were treated in a private practice in Budapest, Hungary, and all surgical procedures were performed by the same practitioner (IU), who has more than 20 years of experience in oral surgery and implant therapies. The prosthetic treatments were performed and restored by the same dentist (IU) and other private practitioners.

Patients were selected for this treatment who required vertical bone regeneration (1) to achieve the necessary bone level to place dental implants and (2) to improve the crown/implant ratio and esthetics. Patients were required to have good physical health and good oral hygiene prior to treatment. All patients were fully informed about the treatment prior to the first surgical procedure and provided written consent for the procedure. Patients were not eligible for this treatment if they were current smokers, consumed excessive alcohol, or had uncontrolled systemic conditions or uncontrolled periodontal disease.

All patients were treated with vertical ridge augmentation using a titanium-reinforced high-density polytetrafluoroethylene (TR-PTFE) membrane (Cytoplast Ti-250 Titanium-Reinforced Membrane, Osteogenics Biomedical) and a combination of autogenous bone and ABBM (Bio-Oss, Geistlich Pharma) (Figs 1 and 2).

The medications, flap design, sutures, and bone harvesting procedure used in this case series have been described previously.^{6,10,14,21} Briefly, the flap design was chosen to ensure primary tension-free closure after the bone grafting procedure despite the increased dimension of the ridge. A remote flap was created by means of crestal and vertical releasing incisions. A full-thickness, midcrestal incision into the keratinized gingiva was performed with a surgical scalpel. The two divergent vertical incisions were placed at least one tooth away from the surgical site. In edentulous areas, the vertical incisions were placed at least 5 mm away from the augmentation site. After primary incisions, periosteal elevators were used to reflect a full-thickness flap beyond the mucogingival junction and at least 5 mm beyond the bone defect. The recipient bone bed was prepared with multiple decorticalization holes using a small round bur.

The autografts were harvested and particulated in a bone mill (R. Quétin Bone-Mill, Roswitha Quétin Dental Products). A 1:1 mixture of autograft and ABBM (ie, composite bone graft) was prepared and then applied

to the defect. The composite bone graft was immobilized and covered with a TR-PTFE membrane that was stabilized with titanium bone tacks (Master Pin Control, Meisinger) and/or titanium screws (Pro-Fix Tenting Screw, Osteogenics Biomedical).

Maxillary vertical cases were combined with a sinus augmentation procedure, when indicated, to achieve additional apical bone height for subsequent implant placement. Defects were measured during the grafting procedures with a calibrated periodontal probe. Vertical bone defects were measured from the most apical portion of the defect to a line connecting the interproximal bone between neighboring teeth, or to the original bone crest of the edentulous area.

If the edges of the membrane were not well adapted, a collagen membrane (Bio-Gide Resorbable Bilayer Membrane, Geistlich Pharma) was placed over the nonresorbable membrane to close any open space in the grafted area (Fig 2). Once the membrane was completely secured, the flap was mobilized to permit tension-free primary closure. A periosteal releasing incision connecting the two vertical incisions was performed to achieve elasticity of the flap. The releasing incision was reinforced until a completely tension-free closure was possible. In posterior mandibular cases, both the lingual and the buccal flaps were advanced. The flap was then sutured in two layers. First, horizontal mattress sutures (GORE-TEX CV-5 Suture, W.L. Gore & Associates) were placed 4 mm from the incision line; then, single interrupted sutures in the same material were placed to close the edges of the flap and leave at least a 4-mm-thick connective tissue layer between the membrane and the oral epithelium. This intimate connective tissue–connective tissue contact provided a barrier to prevent exposure of the membrane. Vertical incisions were closed with single interrupted sutures. The single interrupted sutures were removed after 10 to 14 days postsurgery, and mattress sutures were removed after 2 to 3 weeks.

Any complications in bone graft healing, such as membrane exposure, subsequent infection, and/or morbidity associated with the harvest site, were recorded.

Histologic Processing

Biopsy specimens were to be taken from at least eight patients at the time of implant placement for histologic evaluation, and consent was obtained from these patients for the specimens and evaluation. Cylindrical specimens were obtained from implant osteotomies of selected healed and augmented surgical sites using a trephine bur with an inner diameter of 2.0 mm.

The biopsy specimens were fixed in 4% formalin for 5 to 7 days; dehydrated in a series of ethanols (70%, 80%, 90%, and 100% for 1 day in each concentration);

Fig 1 Representative case of posterior mandibular vertical augmentation.

Fig 1a Panoramic radiograph of preoperative situation. Note that the defect is close to the mental nerve.

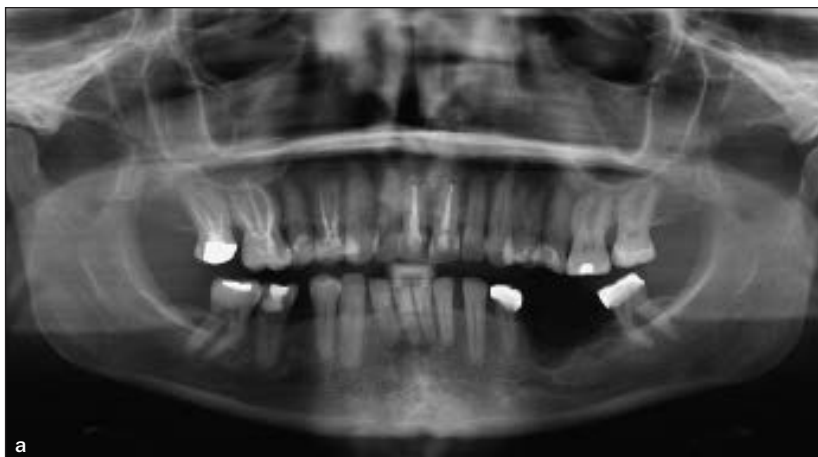


Fig 1b Buccal view of a vertical defect in the posterior mandible.

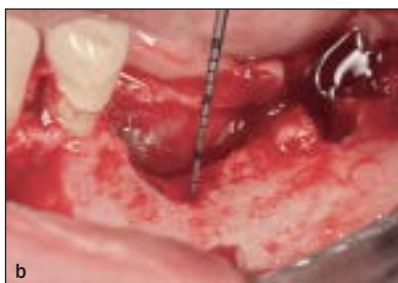

Fig 1c Buccal view of the particulated composite bone graft in place.

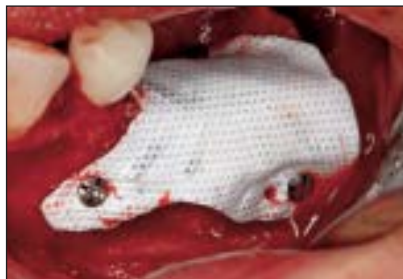
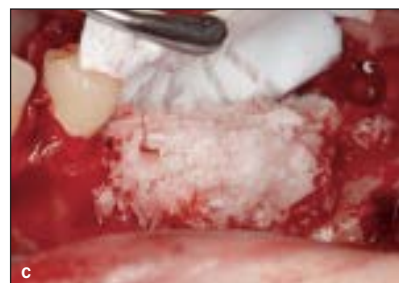
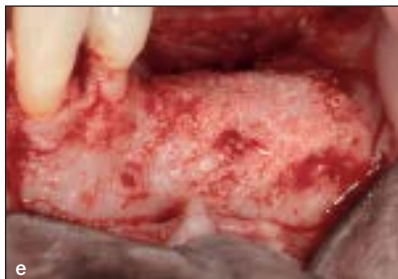Fig 1d The membrane is fixated on the lingual side.



Figs 1e and 1f Buccal and occlusal views of the regenerated bone.

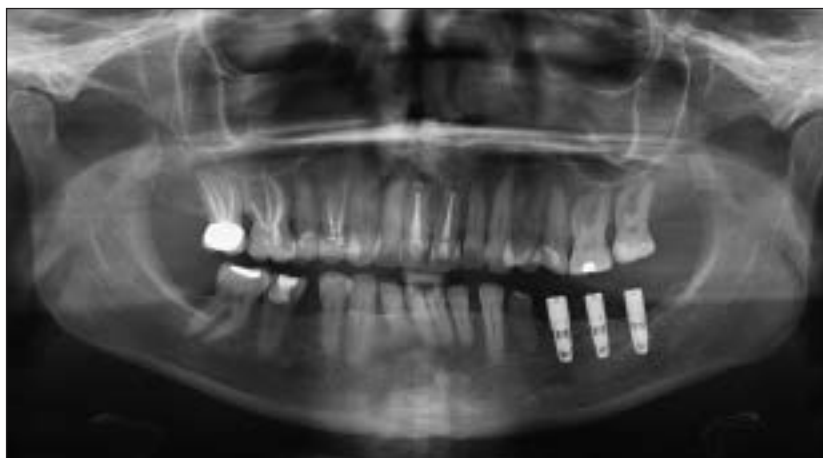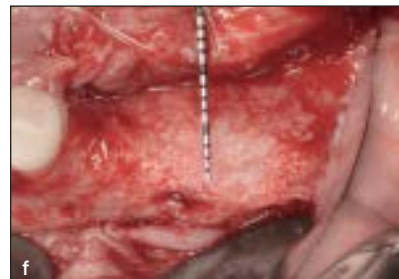


Fig 1g Panoramic radiograph of the regenerated bone with three implants in place. Note the optimal bone situation.

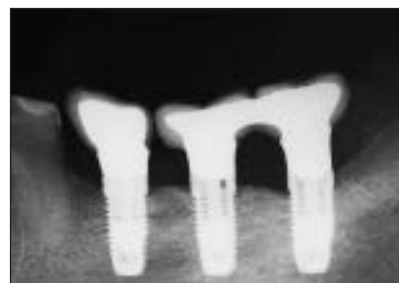
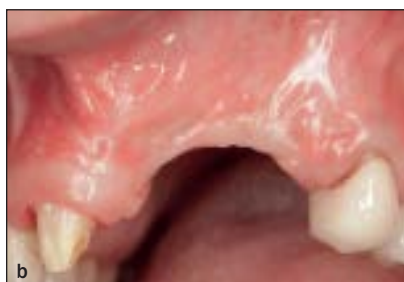
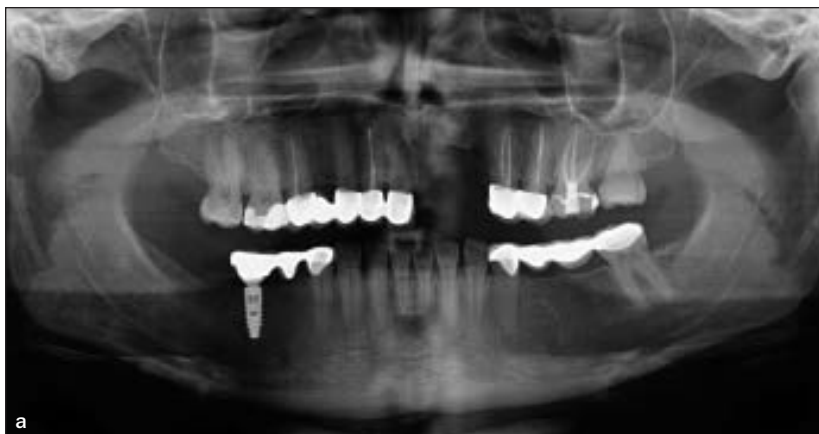Fig 1h Three implants loaded for 12 months in the regenerated bone.

Fig 2 Representative case of an anterior maxillary vertical ridge augmentation.

Fig 2a Panoramic radiograph of preoperative situation. Note the severe defect in the anterior maxilla.



Figs 2b and 2c Buccal views of a 9-mm vertical defect in the anterior maxilla.

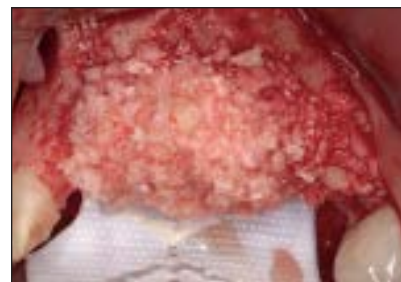
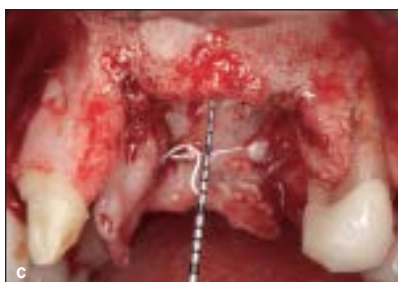
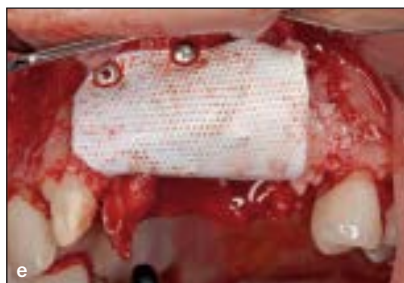
Fig 2d Buccal view of the particulated bone graft in place. The TR-PTFE membrane is fixated on the palate.



Figs 2e and 2f The TR-PTFE membrane is fixated over the bone graft with titanium pins. Note that the right canine was extracted during the procedure, and the membrane is covering only the vertical defect. Distal to the vertical defect, a collagen membrane was used; this was fixated with additional pins.

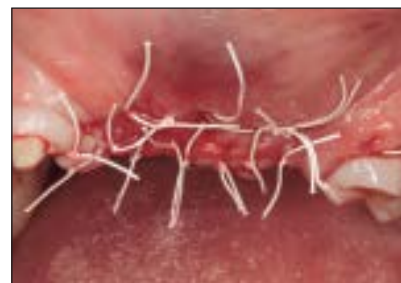
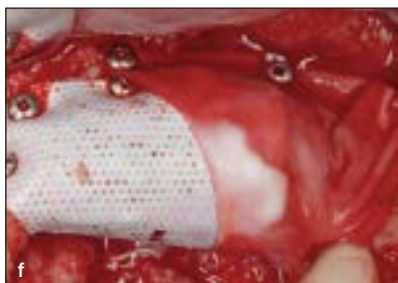
Fig 2g Tension-free flap closure is accomplished using the double-layer suturing technique.

and defatted for 1 day in xylene (Merck). Specimens were then infiltrated, embedded, and polymerized in Technovit 9100 (Heraeus Kulzer) according to the manufacturer's instructions. After polymerization, samples were cut in 500- μ m sections using a low-speed rotary diamond saw (Secotom-50, Struers). The sections were mounted onto opaque acrylic resin slides (Maartin) and ground to a final thickness of approximately 60 μ m on a rotating grinding plate (Stuers). Specimens were subsequently stained with Azur II (Sigma-Aldrich Chemie) and pararosaniline (Merck).

Histologic and Histomorphometric Evaluations

Imaging was performed with an Axio Imager M1 microscope equipped with a digital AxioCam HRC (Carl Zeiss). Histomorphometric analysis was achieved with analySIS FIVE software (Soft Imaging System).

Data Analysis

All data were analyzed by descriptive methods, and means, standard deviations, medians, ranges, and interquartile ranges were calculated using SAS statistical software (version 9.2, SAS Inc).

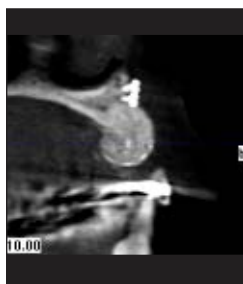
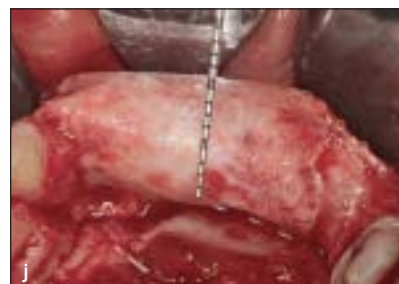
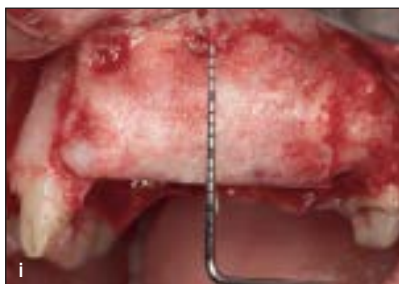
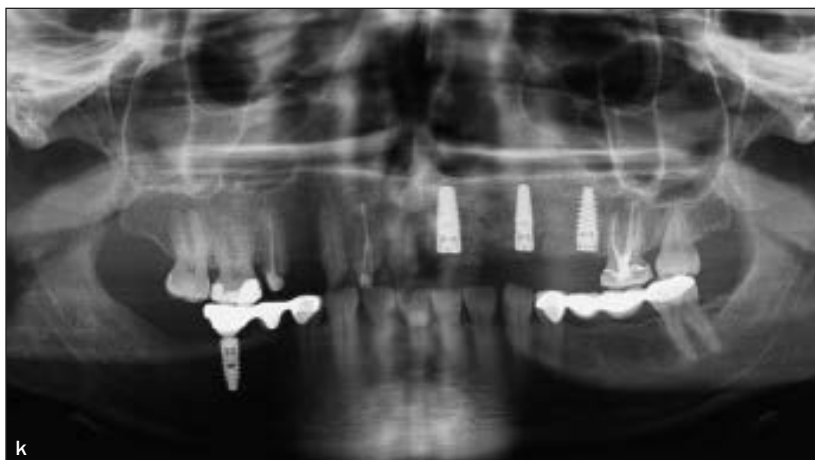Fig 2h Cross-sectional view of a cone-beam computed tomogram demonstrating the regenerated bone.



Figs 2i and 2j Buccal and occlusal views of the regenerated bone after 8.7 months of healing.

Fig 2k Three implants were placed in the regenerated bone.



RESULTS

This prospective case series reports on the use of a new TR-PTFE membrane in patients who reported to a clinical practice and required vertical bone augmentation prior to implant placement.

Clinical Observations

Twenty vertical ridge augmentation procedures were carried out in 19 patients (4 men, 15 women; mean age, 43.4 years). Five patients required simultaneous maxillary sinus floor augmentation (Table 1).

Intraoral bone grafts were harvested from the posterior mandible in 18 cases (90%), the posterior maxilla in one case (5%), and the chin in one case (5%). All patients presented with vertical bone defects. Five patients (five sites) had defects in the posterior maxilla and were treated simultaneously with sinus and vertical augmentation.

Bone regeneration was evaluated clinically at the time of membrane removal. The same reference points were used to ensure consistent measurements of vertical bone gain. The reference points were the line connecting the interproximal bone height between neighboring teeth, or the line connecting the interproximal bone height to the original bone crest of the edentulous area.

In general, all treated defect sites exhibited excellent bone formation, with an average of 5.45 mm (range, 2 to 9 mm; standard deviation 1.93 mm) of vertical augmentation achieved overall (see Table 1). None of the cases demonstrated bone resorption throughout the follow-up period.

The healing period was uneventful in all cases, and no complications, such as membrane exposure, infection, or harvest site morbidity, were observed. Postoperative swelling was remarkable in most cases, with maximum swelling at 48 hours postoperatively. Swelling

Table 1 Surgical Sites Treated with Vertical Ridge Augmentation for Subsequent Implant Placement

Patient no. (surgical site no.)	Sex	Age (y)	Arch	Simultaneous sinus augmentation?	Healing time (mo)	Vertical gain (mm)	Histology
1 (1)	Male	68	Maxilla	Yes	8.0	6.0	Yes
2 (2)	Male	63	Maxilla	Yes	7.6	5.0	Yes
3 (3)	Female	26	Maxilla	No	6.4	4.0	Yes
4 (4)	Female	34	Maxilla	No	6.3	4.0	Yes
5 (5)	Female	26	Maxilla	No	9.6	6.0	Yes
6 (6)	Female	54	Maxilla	No	7.7	2.0	Yes
7 (7)	Female	46	Mandible	No	8.3	8.0	Yes*
8 (8)	Female	44	Maxilla	No	12.0	7.0	Yes*
9 (9)	Female	49	Maxilla	No	11.1	7.0	–
10 (10)	Female	47	Mandible	No	20.6	5.0	–
11 (11)	Male	47	Maxilla	Yes	11.5	5.0	–
11 (12)			Mandible	No	8.8	4.0	–
12 (13)	Female	34	Maxilla	No	8.7	9.0	–
13 (14)	Female	58	Maxilla	No	10.2	3.0	–
14 (15)	Female	38	Maxilla	Yes	10.2	5.0	–
15 (16)	Female	33	Maxilla	No	8.5	5.0	–
16 (17)	Female	24	Maxilla	No	9.0	9.0	–
17 (18)	Male	55	Maxilla	Yes	11.5	7.0	–
18 (19)	Female	42	Maxilla	No	9.4	5.0	–
19 (20)	Female	36	Maxilla	No	8.9	3.0	–
N (data available)	19	19	20	20	20	20	8
Mean (SD)	–	43.4 (12.6)	–	–	9.72 (3.02)	5.45 (1.93)	–
Median	–	44.0	–	–	9.0	5.0	–
Interquartile range	–	(34.0, 51.5)	–	–	(8.2, 10.4)	(4.0, 7.0)	–
Range	–	24–68	–	–	(6.3–20.6)	(2.0–9.0)	–

SD = standard deviation.

*Two specimens were obtained for histologic analysis.

subsided gradually but was still visible at 1 week and disappeared completely after 10 days. Postoperative discomfort was primarily associated with tension from the swelling, but pain was minimal. No major complications, such as hemorrhage, postoperative infection, mandibular fracture, or neurosensory disturbances, occurred in any patients in this case series. There were no device-related adverse effects related to the use of the membrane in these augmentation procedures. Upon reopening of the surgical site at implant placement, the tissue appeared healthy, with a strong periosteal layer between the soft tissue and the bone, similar to results previously reported for nonresorbable and collagen membranes.

Histologic and Histomorphometric Findings

Eight specimens were examined histologically. The histologic samples were taken, after a mean of 8.24

months of graft healing, during implant placement from the implant osteotomies utilizing a 2-mm trephine bur for implant site preparation. Histomorphometric analysis demonstrated that autogenous or regenerated bone represented a mean of 36.6% of the specimens; of this, 19.6% was newly formed bone and 17% was grafted bone. Grafted autogenous particles demonstrated ongoing remodeling. On average, ABBM accounted for 16.6% of the area and marrow space accounted for 46.8%. Representative histologic views are presented in Figs 3a to 3d. In all biopsy specimens evaluated, ABBM particles were connected with a dense network of newly formed bone of various degrees of maturation. In all specimens, the marrow space was well perfused with blood vessels, and no inflammatory response or foreign-body reaction was noted in any of the specimens.

Fig 3a Overview of a histologic section taken after 9 months of graft healing from the patient shown in Fig 2 (original magnification $\times 50$).



Fig 3b Extra- and intraosseous deposition of new bone on grafted bone particles can be seen.

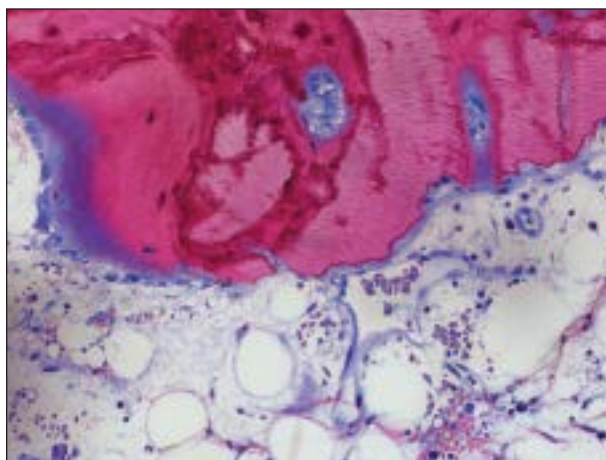
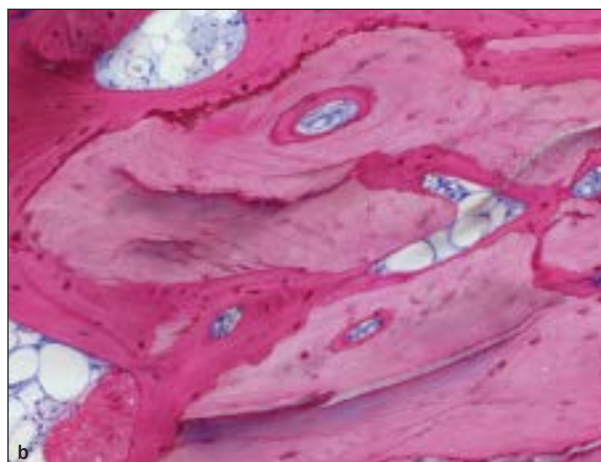


Fig 3c A seam of osteoblasts is adding osteoid and new bone to bone chips; resorption of autogenous graft particles, well-perfused bone marrow, and an absence of inflammatory signs are apparent (original magnification $\times 200$).

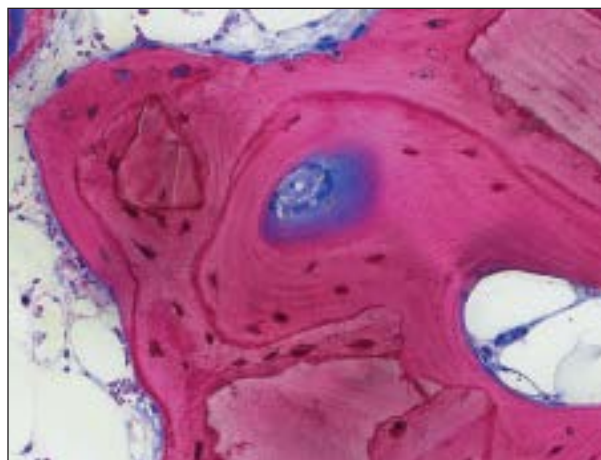


Fig 3d ABBM and grafted bone are primarily embedded in woven bone next to layers of lamellar bone osteon formation; some remodeling has taken place (original magnification $\times 200$). The connective tissue shows no signs of inflammatory reactions.

DISCUSSION

The case series presented herein demonstrates that the combination of particulated augmentation material (ie, autogenous bone and ABBM) and a nonresorbable titanium-reinforced membrane can be safe and effective for vertical augmentation of deficient ridges in the maxilla or mandible. Healing of the bone graft was uneventful in all patients in this prospective case series. The use of the membrane reported herein has shown good soft tissue compatibility, and no membrane exposures or infections occurred at any of the surgical sites. These results are similar to a study reported previously¹⁴ but are significantly improved versus the complication rates reported in earlier clinical studies of vertical augmentation with GBR (ranging from 13.6% to 17%). These earlier reports also included membrane exposures and/or subsequent

infections.^{9-11,14,22} The technique employed in this vertical augmentation study is essentially the same technique reported previously.^{10,21} However, this prospective case series represents a time period during which vertical ridge augmentation was considered routine clinical practice and does not represent the initial learning curve for this type of procedure.

The same new, but not reinforced, PTFE membrane has been used for a different indication: extraction socket treatment. In that treatment, these membranes were left intentionally exposed to the oral environment.²³ The authors reported no infectious complications, in contrast to previous reports for expanded PTFE membranes, in which membrane exposures usually resulted in infections and impaired bone formation. The authors reporting on the new PTFE membrane speculated that the low porosity of these membranes created a resistance to bacterial incorporation. In the current

study, the soft tissues were intentionally closed above the membranes. Since the soft tissue was intentionally closed and no membrane exposures occurred in this case series, the current authors cannot confirm the speculation made by other authors reporting on this new membrane. Because of the positive results of the current investigation, primary closure with this new TR membrane is still indicated and considered of primary importance to the success of such complex cases.

In this case series, there was a mean vertical bone increase of 5.45 mm (standard deviation 1.93 mm), with some sites gaining up to 9 mm. None of the cases showed bone height gain that was less than the space created by the membrane. Similar results were reported in previous studies,^{10,12,14} whereas somewhat less bone gain was reported by others.^{13,22} The differences may be attributed to differences in the severity of the initial defects treated. There has been no evidence of bone resorption over time.

In these sites treated with a mixture of autogenous bone and ABBM, the ABBM particles showed good incorporation with the newly formed ridge. This clinical evidence is supported by the available histologic specimens of the augmented areas, which showed that the ABBM particles were connected by a dense network of newly formed bone. This is in agreement with previous reports on horizontal and vertical ridge augmentation using a mixture of autogenous bone and ABBM.^{6,7,13} In addition, the use of ABBM in these procedures may lessen the need for harvested autogenous bone and may generally lead to decreased morbidity and therefore increased patient comfort and satisfaction with these regenerative procedures. The absence of major complications in any of the harvest sites in this case series supports the potential benefit of ABBM for these types of procedures.

This prospective case series demonstrates the feasibility of a new TR-PTFE membrane in GBR for vertical ridge augmentation and subsequent implant placement. As stated previously, the results with this new membrane are similar to the bone gain reported by other vertical augmentation studies. However, the positive results obtained in this case series need to be replicated by larger randomized and controlled clinical trials of the regenerative phase, implant placement, long-term stability of the regenerated bone, and implant survival.

CONCLUSION

Within the limitations of this case series, the treatment of vertically deficient alveolar ridges with a guided bone regeneration technique using autogenous bone with the addition of anorganic bovine bone-derived

mineral and a titanium-reinforced, high-density polytetrafluoroethylene barrier membrane can be regarded as successful. Histologic evaluation showed that the anorganic bovine bone-derived mineral particles were connected with a dense network of newly formed bone of varying degrees of maturation. Nevertheless, randomized, controlled clinical studies are necessary to prove that the investigated membrane, as well as other bone substitutes, can support healing in the same way as was demonstrated in this case series.

ACKNOWLEDGMENTS

The authors would like to thank Annette Lindner for her excellent technical assistance in histologic preparations and histomorphometric measurements. The authors reported no conflicts of interest related to this study.

REFERENCES

1. Buser D, Brägger U, Lang NP, Nyman S. Regeneration and enlargement of jaw bone using guided tissue regeneration. *Clin Oral Implants Res* 1990;1:22–32.
2. Dahlin C, Andersson L, Linde A. Bone augmentation at fenestrated implants by an osteopromotive membrane technique. A controlled clinical study. *Clin Oral Implants Res* 1991;2:159–165.
3. Jovanovic SA, Spiekermann H, Richter EJ. Bone regeneration around titanium dental implants in dehiscence defect sites: A clinical study. *Int J Oral Maxillofac Implants* 1992;7:233–245.
4. Buser D, Ingimarsson S, Dula K, Lussi A, Hirt HP, Belser UC. Long-term stability of osseointegrated implants in augmented bone: A 5-year prospective study in partially edentulous patients. *Int J Periodontics Restorative Dent* 2002;22:109–117.
5. Zitzmann NU, Schärer P, Marinello CP. Long-term results of implants treated with guided bone regeneration: A 5-year prospective study. *Int J Oral Maxillofac Implants* 2001;16:355–366.
6. Urban IA, Nagursky H, Lozada JL. Horizontal ridge augmentation with a resorbable membrane and particulated autogenous bone with or without anorganic bovine bone-derived mineral: A prospective case series in 22 patients. *Int J Oral Maxillofac Implants* 2011;26:404–414.
7. Urban IA, Nagursky H, Lozada JL, Nagy K. Horizontal ridge augmentation with a collagen membrane and a combination of particulated autogenous bone and anorganic bovine bone-derived mineral: A prospective case series in 25 patients. *Int J Periodontics Restorative Dent* 2013;33(3):299–307.
8. Urban IA. Simultaneous sinus and horizontal augmentation utilizing a resorbable membrane and particulated bone graft: A technical note and 7-year follow-up of a case. *Eur J Oral Surg* 2011;2:19–24.
9. Simion M, Trisi P, Piattelli A. Vertical ridge augmentation using a membrane technique associated with osseointegrated implants. *Int J Periodontics Restorative Dent* 1994;14:496–511.
10. Tinti C, Parma-Benfenati S. Vertical ridge augmentation: Surgical protocol and retrospective evaluation of 48 consecutively inserted implants. *Int J Periodontics Restorative Dent* 1998;18:434–443.
11. Simion M, Jovanovic SA, Trisi P, Scarano A, Piattelli A. Vertical ridge augmentation around dental implants using a membrane technique and autogenous bone or allografts in humans. *Int J Periodontics Restorative Dent* 1998;18:18–23.
12. Simion M, Jovanovic SA, Tinti C, Parma-Benfenati S. Long-term evaluation of osseointegrated implants inserted at the time or after vertical ridge augmentation. A retrospective study on 123 implants with 1-5 year follow-up. *Clin Oral Implants Res* 2001;12:35–45.

13. Simion M, Fontana F, Rasperini G, Maiorana C. Vertical ridge augmentation by expanded-polytetrafluoroethylene membrane and a combination of intraoral autogenous bone graft and deproteinized anorganic bovine bone (BioOss). *Clin Oral Implants Res* 2007;18:620–629.
14. Urban IA, Jovanovic S, Lozada JL. Vertical ridge augmentation using guided bone regeneration (GBR) in three clinical scenarios prior to implant placement: A retrospective study of 35 patients 12 to 72 months after loading. *Int J Oral Maxillofac Implants* 2009;24:502–510.
15. Urban IA, Caplanis N, Lozada JL. Simultaneous vertical guided bone regeneration (GBR) and guided tissue regeneration (GTR) in the posterior maxilla using recombinant human platelet-derived growth factor (rhPDGF). A case report. *J Oral Implantol* 2009;35:251–256.
16. Jovanovic SA, Schenk RK, Orsini M, Kenney EB. Supracrestal bone formation around dental implants: An experimental dog study. *Int J Oral Maxillofac Implants* 1995;10(1):23–31.
17. Esposito M, Grusovin M, Worthington H, Coulthard P. Interventions for replacing missing teeth: Bone augmentation techniques for dental implant treatment. *Cochrane Database Syst Rev* 2006:CD003607.
18. Aghaloo TL, Moy PK. Which hard tissue augmentation techniques are the most successful in furnishing bony support for implant placement? *Int J Oral Maxillofac Implants* 2007;22:49–70.
19. Esposito M, Grusovin MG, Coulthard P, Worthington HV. The efficacy of various bone augmentation procedures for dental implants: A Cochrane systematic review of randomized controlled clinical trials. *Int J Oral Maxillofac Implants* 2006;21:696–710.
20. Hämmerle CH, Jung RE, Feloutzis A. A systematic review of the survival of implants in bone sites augmented with barrier membranes (guided bone regeneration) in partially edentulous patients. *J Clin Periodontol* 2002;29(suppl 3):226–231.
21. Urban IA, Guided bone regeneration: Vertical growth. In: Sonick M, Hwang D (eds). *Implant Site Development*. West Sussex, UK: Wiley-Blackwell, 2012:216–231.
22. Merli M, Lombardini F, Esposito M. Vertical ridge augmentation with autogenous bone grafts 3 years after loading: Resorbable barriers versus titanium-reinforced barriers. A randomized controlled clinical trial. *Int J Oral Maxillofac Implants* 2010;25(4):801–807.
23. Fotek PD, Neiva RF, Wang HL. Comparison of dermal matrix and polytetrafluoroethylene membrane for socket bone augmentation: A clinical and histologic study. *J Periodontol* 2009;80:776–785.